



# Clinical Uses of Pelvic Floor Ultrasound



## A colorectal surgeon's view

Marianne Starck, M.D., Ph.D.

Pelvic Floor Center, Malmö University Hospital, Malmö, Sweden

### ■ Why should you use pelvic floor ultrasound?

Pelvic Floor anatomy is still not fully understood. For that reason, ultrasound is valuable for both research and clinical purposes. Dr. John Delancey has done extensive research using MR of the pelvic floor, but there are still many unanswered questions about pelvic dysfunction and the normal anatomy.

Pelvic dysfunction can be difficult to diagnose clinically, especially on patients who have previously undergone surgical procedures.

To a certain extent, pelvic floor function can be examined clinically. But in some patients digital palpation of the function and movement of the bladder and bowel can't be completely understood without ultrasound.

Ultrasound helps us to see to what extent organs in the pelvis "move" when a patient is asked to perform squeeze or Valsalva maneuvers.

I believe that in the future ultrasound will also be used more often post-operatively.

Today we know very little about how well a successful (from the patient's point of view) surgical outcome is correlated with various anatomic reconstructions for pelvic floor disorders.

### ■ Who should perform ultrasound examinations?

Any physician or practitioner who treats the patient should incorporate pelvic floor ultrasound into the clinical examination before deciding on a plan of treatment.

What we see today are obstetricians using ultrasound for complete obstetric examinations as well as an increasing number of colorectal surgeons using ultrasound not only for anal sphincter damage but in connection with anal fistula surgery as well.

### ■ Why use the multicompartiment pelvic floor ultrasound method?

This method combines anatomical examinations with functional ultrasound examinations. By using endovaginal and endoanal as well as perineal ultrasound, we can examine all compartments of the pelvic floor: anterior (area around the urinary structures), middle (around the vagina) and posterior (around the anorectal structures).

**Perineal ultrasound** is used to get an overview of the pelvic floor and to perform functional studies.

**Endoanal** and **endovaginal** scanning techniques, however, allow us to see both superficial and deeper pelvic structures in more detail. Endovaginal scanning can also in some instances provide us with important information about function.

## ■ What can you see with each of the individual examinations that make up a complete pelvic floor ultrasound examination?

Many structures can be seen in more than one of the examinations, which is a big help. What you see during one examination, you can confirm with another.

### 1: Transperineal examination (8802)

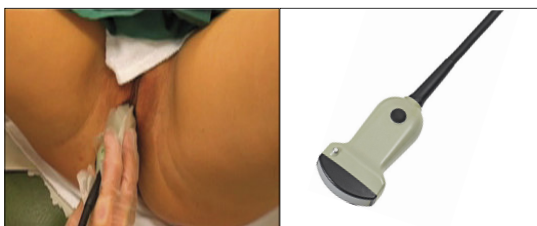

Fig. 1a. Transperineal examination with 8802 transducer.

This gives you a general overview of the pelvic floor. You can see the bladder and urethra and their relation to the vagina and anus-rectum. You can also get an overview of the anal canal (although not in detail), the anorectal angle and whether the patient has a rectocele when relaxed. TVT tapes can also be seen.

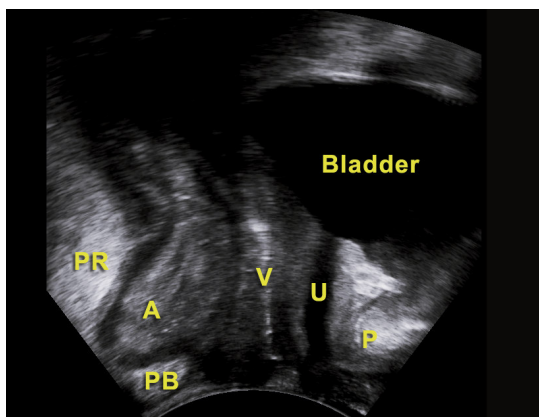


Fig. 1b. Normal ultrasound view during a sagittal perineal scan.

(A = anal canal, P = pubic bone, PB = perineal body, PR = puborectalis, U = urethra, V = vagina)

During squeeze and Valsalva maneuvers, movement of the pelvic floor structures can

be visualized. You can also see whether the patient uses the puborectalis during squeeze maneuvers and whether the bladder descends during Valsalva or if the patient pushes down a rectocele. Sometimes, but not always, you can see enterocele during Valsalva maneuvers.

### 2: Endovaginal examination (2052)

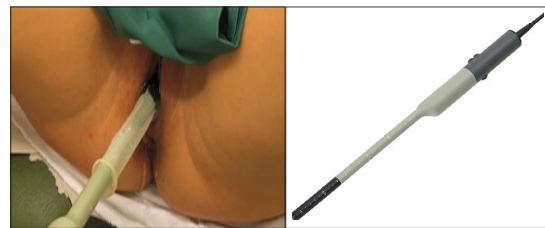

Fig. 2a. Endovaginal examination with 2052 transducer.

With this high-frequency rotating transducer, you can use 3D to see detailed structures in the anterior and posterior compartment in the same scan. You can see these at all levels, from the most proximal to the most distal. This is an anatomic examination, not a dynamic examination.

Four important levels can be defined from the complete 3D scan.

Level 1: At the highest level, the base of the bladder can be seen anteriorly and the rectum posteriorly.

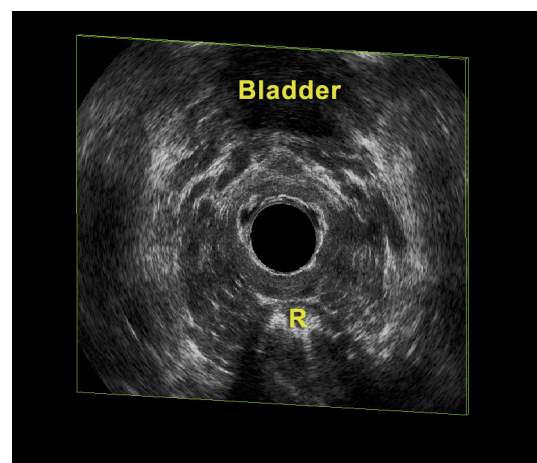


Fig. 2b. Level 1 as seen with 2052. (R = rectum)

Level 2: The Upper part of the urethra and the levator ani are seen.

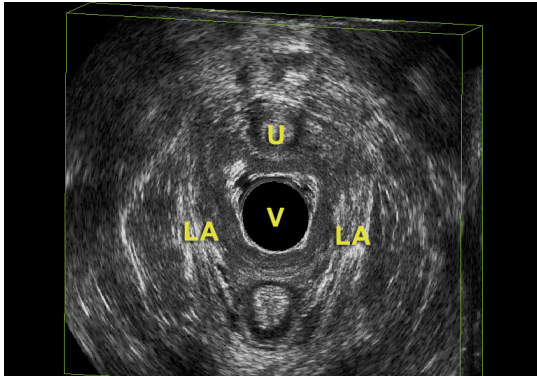


Fig. 2c. Level 2 as seen with 2052. (LA = levator ani, U = urethra, V = vagina)

Level 3: The pubic bone can be seen at 12 o'clock and the levator ani attachment to it can be seen. Posteriorly the puborectalis is seen.

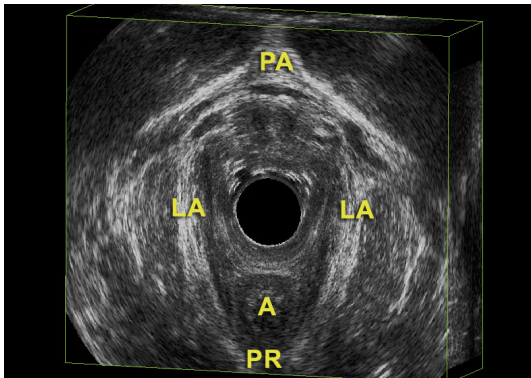


Fig. 2d. Level 3 as seen with 2052. (A = anal canal, LA = levator ani, PA = pubic arch, PR = puborectalis)

Level 4: The lowest level, where the superficial perineal muscles, the perineal body and the mid to lower anal canal can be visualized.

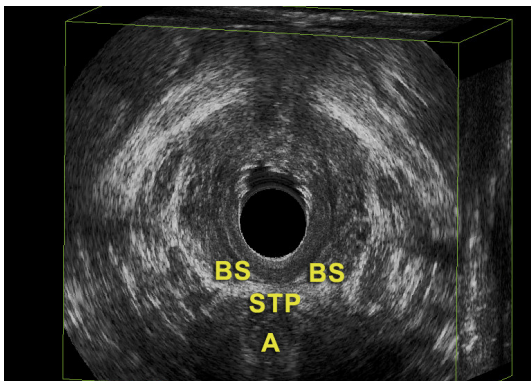


Fig. 2e. Level 4 as seen with 2052. (A = anal canal, BS = bulbospongiosus, STP = superficial transverse perineal)

### 3: Endovaginal examination (8848)

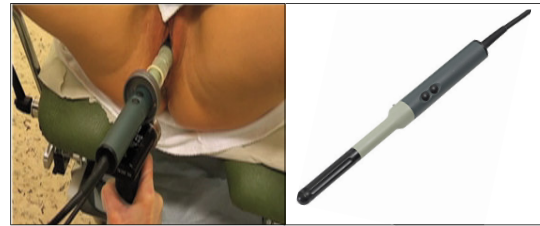

Fig. 3a. Endovaginal examination with 8848 transducer.

This combines 3D with a dynamic examination.

**Anatomy:** A 3D examination with the 8848 differs from one with the 2052, where we focus mostly on the levator muscles and defects.

With the 8848 we are able to see anterior details of the urethra, the rhabdosphincter muscle, bladder neck and muscle layers of the bladder.

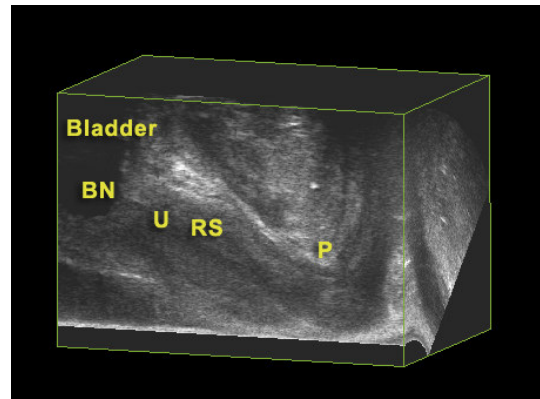


Fig 3b. Anterior compartment seen with 8848 transducer. (BN = bladder neck, P = pubic bone, RS = rhabdosphincter, U = urethra)

Posteriorly, you can see the anorectal junction, the proximal part of the anal canal and the perineal structures, especially the perineal body.

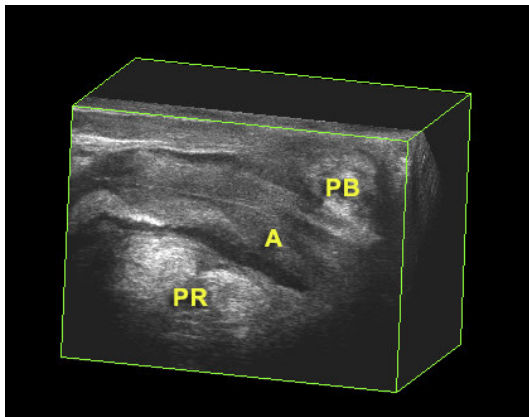


Fig 3c. Posterior compartment seen with 8848. (A = anal canal, PB = perineal body, PR = puborectalis)

*Dynamic exam:* The 8848 can also be used to perform a dynamic examination and to evaluate the patient's ability to perform squeeze maneuvers. However, it is sometimes difficult to see enterocele, cystocele and rectocele due to the transducer's presence in the vagina.

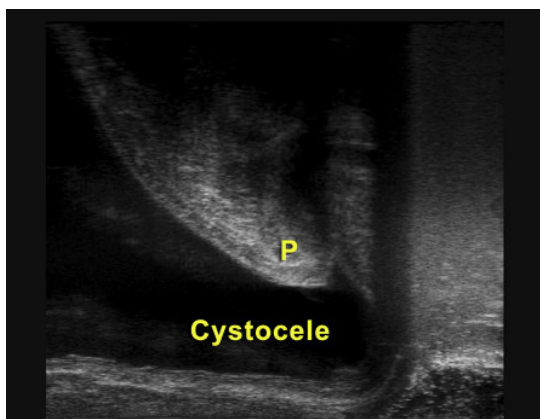


Fig 3d. Cystocele as seen with 8848. (P = pubic bone)

#### 4: Endoanal 2052 examination

This examination focuses on the anal canal as it is difficult to see the whole anal canal with other pelvic floor ultrasound methods. During an endoanal examination with the 2052 you can see puborectalis, the internal and external sphincter transverse perineal muscle and sometimes the perineal body.

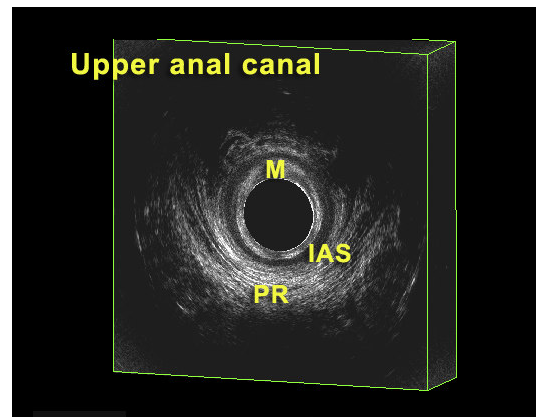


Fig 4a. Upper anal canal as seen with 2052. (IAS = internal anal sphincter, M = mucosa, PR = puborectalis)

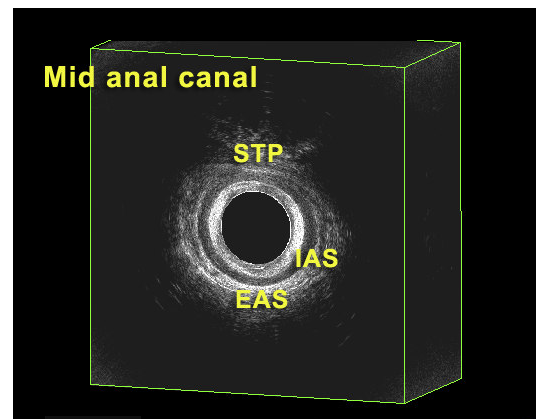


Fig 4b. Mid anal canal as seen with 2052. (IAS = internal anal sphincter, EAS = external anal sphincter, STP = superficial transverse perineal)

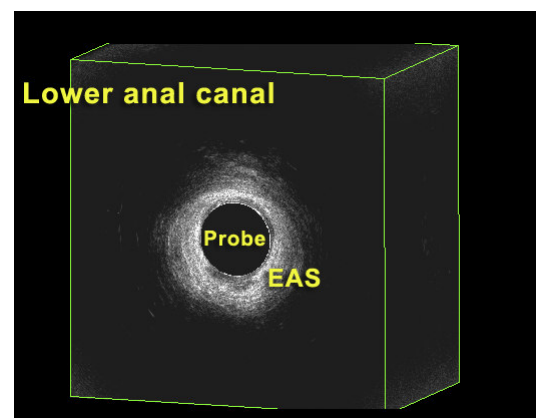


Fig 4c. Lower anal canal as seen with 2052. (EAS = external anal sphincter)

## ■ Clinical applications – what patients do you examine with pelvic floor ultrasound?

We perform full pelvic floor ultrasound examinations on patients with fecal incontinence and outlet disorders.

### Fecal Incontinence

#### Sphincter and perineal defects

It is not clinically possible to know the exact extent of a sphincter defect. This is why all patients with fecal incontinence should have a pelvic floor ultrasound examination. The size of such a defect is important for determining whether the patient requires surgery, and if so, what surgical course to take.

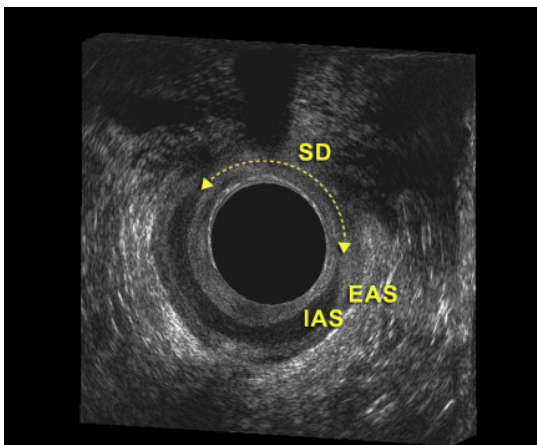


Fig 5. External and internal sphincter defects. (EAS = external anal sphincter, IAS = internal anal sphincter, SD = sphincter defect)

If the ultrasound image shows defects in perineal structures (the transverse perineii and or the perineal body) as well as in the sphincter, the current approach is to offer the patient perineal and sphincter reconstruction at the same time. Patients can occasionally be offered perineal reconstruction if they suffer from incontinence without the presence of sphincter damage but with perineal damage.

#### Levator muscle defects

If pelvic floor ultrasound scanning shows that a patient suffers from defects to the levator musculature without any other pelvic defects,

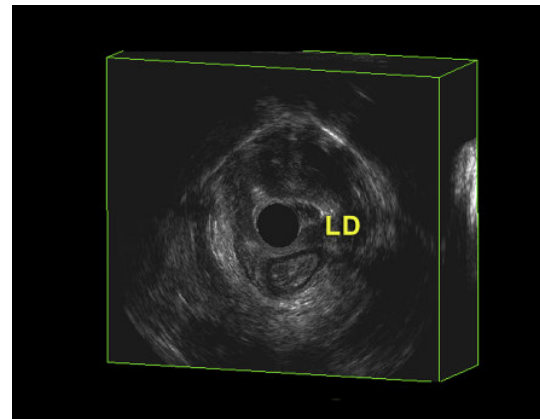


Fig 6. Levator defect (LD).

we unfortunately can't make any kind of surgical repairs.

If a woman is considering childbirth (especially if she has some incontinence symptoms), knowing whether she has a levator defect could affect the decision as to whether a vaginal delivery is advisable.

Even though surgery is not at present possible for these cases, the new possibilities with pelvic floor ultrasound can shed light on the problem and give us hope that in the future we may be able to help these patients.

#### Weak posterior vaginal wall

Certain fecal incontinence patients have a weak posterior vaginal wall (rectocele) that is a contributing factor to incontinence and incomplete evacuation. The use of defecography as a diagnostic tool has not been very successful, in my opinion. Dynamic pelvic floor ultrasound can help us evaluate the type and size of the defect objectively and in the future I hope it will be able to help us determine patients' suitability for surgery.

#### Outlet Disorders

This is a difficult patient group to evaluate and treat. Pelvic floor ultrasound can help determine whether the patient suffers from anismus, a difficult condition to verify through clinical examination.

Pelvic floor ultrasound also helps a practitioner to objectively judge enterocele as well as rectocele.

I believe that in the future this will help us in the selection of patients for posterior repair.

### ■ How else does pelvic floor ultrasound affect patient care?

It is important to remember that knowing whether or not the patient has anatomical or functional abnormalities is valuable in itself. Pelvic floor ultrasound gives us that information.

In addition to the specific clinical examples mentioned above, I know from my own experience that patients themselves benefit from this information. It is easy to add the ultrasound examination – it takes only about 10 minutes. Showing patients the ultrasound images and discussing the results with them engages the patients and motivates them to adhere to conventional treatments.

On the other hand, if abnormalities are not found, knowing that the anatomical structures and function have been completely examined and found normal provides valuable reassurance for the patient.

### ■ Conclusion

Pelvic floor ultrasound is a method that, combined with a clinical examination, will improve the diagnostic confidence in patients with pelvic floor dysfunctions.

### ■ References

- Bartram CI, Frudinger A.**  
*Handbook of Anal Endosonography.*  
Petersfield, UK and Bristol, PA. Wrightson Biomedical Publishing Ltd;1997.
- Dietz HP.**  
Why pelvic floor surgeons should utilize ultrasound imaging.  
*Ultrasound Obstet Gynecol* 2006;28(5):629-634.
- Dietz HP, Shek KL.**  
Tomographic ultrasound imaging of the pelvic floor: which levels matter most?  
*Ultrasound Obstet Gynecol* 2009;33(6):698-703.
- Margulies RU, Hsu Y, Kearney T et al.**  
Appearance of the levator ani muscle subdivisions in magnetic resonance images.  
*Obstet Gynecol* 2006 May; 107(5): 1064-1069.
- Santoro GA, Wiczorek AP, Stankiewicz A et al.**  
High-resolution three-dimensional endovaginal ultrasonography in the assessment of pelvic floor anatomy: a preliminary study.  
*Int Urogynecol J Pelvic Floor Dysfunct* 2009; 20(10):1213-1222.
- Shobeiri SA, Leclaire E, Nihira MA et al.**  
Appearance of the levator ani muscle subdivisions in endovaginal three-dimensional ultrasonography.  
*Obstet Gynecol* 2009 Jul;114(1): 66-72.
- Starck M, Bohe M, Fortling B et al.**  
Endosonography of the anal sphincter in women of different ages and parity.  
*Ultrasound Obstet Gynecol* 2005;25:169-176.
- Stoker J, Taylor SA, Delancey JOL (eds).** *Imaging Pelvic Floor Disorders, 2nd ed.* New York. Springer-Verlag New York, LLC;2008.



World Headquarters:  
Mileparken 34 · DK-2730 · Herlev · Denmark  
Tel: +45 4452 8100 · Fax: +45 4452 8199 · www.bkmed.com  
A wholly owned subsidiary of Analogic Corporation